

# Voriconazole plasma monitoring

A C Pasqualotto,<sup>1,2</sup> M Shah,<sup>3</sup> R Wynn,<sup>4</sup> D W Denning<sup>1,2,5</sup>

<sup>1</sup>School of Medicine, University of Manchester, UK; <sup>2</sup>Wythenshawe Hospital, Manchester, UK; <sup>3</sup>Burn Unit, Booth Hall Children's Hospital, Manchester, UK; <sup>4</sup>Department of Haematology, Royal Manchester Children's Hospital, Manchester, UK; <sup>5</sup>Regional Mycology Laboratory, Manchester, UK

Correspondence to: Alessandro Pasqualotto, Education and Research Centre, Wythenshawe Hospital, Southmoor Road, Manchester, M23 9LT, UK; [acpasqualotto@hotmail.com](mailto:acpasqualotto@hotmail.com)

Accepted 29 January 2008  
Published Online First  
5 February 2008

## ABSTRACT

**Aims:** Very little information is available regarding the use of voriconazole drug monitoring in children with invasive fungal infections. The purpose of this study was to report the cases of five paediatric patients treated with voriconazole, in which plasma levels were used to monitor therapy.

**Methods:** Five children treated with voriconazole were included in this case series. Voriconazole plasma levels were determined using either a bioassay or liquid chromatography–tandem mass spectrometry.

**Results:** The patients' ages ranged from 2 to 10 years old (mean 6.2 years). Three patients had acute leukaemia and two had suffered severe burn injuries. Doses administered varied from 3.4 mg/kg every 12 h to 8.1 mg/kg every 8 h. Plasma voriconazole concentrations were unpredictable for these paediatric patients. Subtherapeutic levels were frequently observed, despite progressive increments in dosage. For others, voriconazole levels markedly increased after a small increment in dosage.

Phenobarbitone caused important drug interactions with voriconazole for two of the patients.

**Conclusions:** The dose administered did not correlate with exposure as measured by plasma levels of voriconazole. While the optimal dosage for voriconazole in children is still unknown, drug monitoring seems warranted to ensure adequate exposure, and after dose increments to prevent excessive exposure. Drug interactions significantly altered exposure.

Voriconazole is a second-generation triazole anti-fungal agent with enhanced *in vitro* activity against various fungi. It is considered to be a first line primary therapy for invasive aspergillosis, and is equivalent to a regimen of amphotericin B followed by fluconazole for the treatment of candidaemia. However, since clinical studies with voriconazole have included only adults (>11–18 years old), experience in paediatric patients has been limited to case reports or series of cases. Accordingly, the optimal dose of voriconazole in children has not been fully established, but it is believed to be greater than adult dosing. The purpose of this paper is to report the cases of five

## METHODS

Five children treated in different hospitals in the United Kingdom were studied. All patients received voriconazole as a loading dosage (range, 5.2–6.0 mg/kg intravenously in two dosages) and 3.4–6 mg/kg intravenously twice daily thereafter.

Voriconazole plasma levels were determined at the Regional Mycology Laboratory, Salford. Before 2002, samples were processed using a bioassay. In recent years, voriconazole has been measured by liquid chromatography–tandem mass

spectrometry. This validated method is sensitive and faster than the bioassay or high-pressure liquid chromatography–UV methods.<sup>1</sup> Targeted trough voriconazole levels were 0.25–6.0 µg/ml.<sup>2</sup> The lower limit of quantification was 0.1 µg/ml. Concentrations below that limit were recorded as zero.

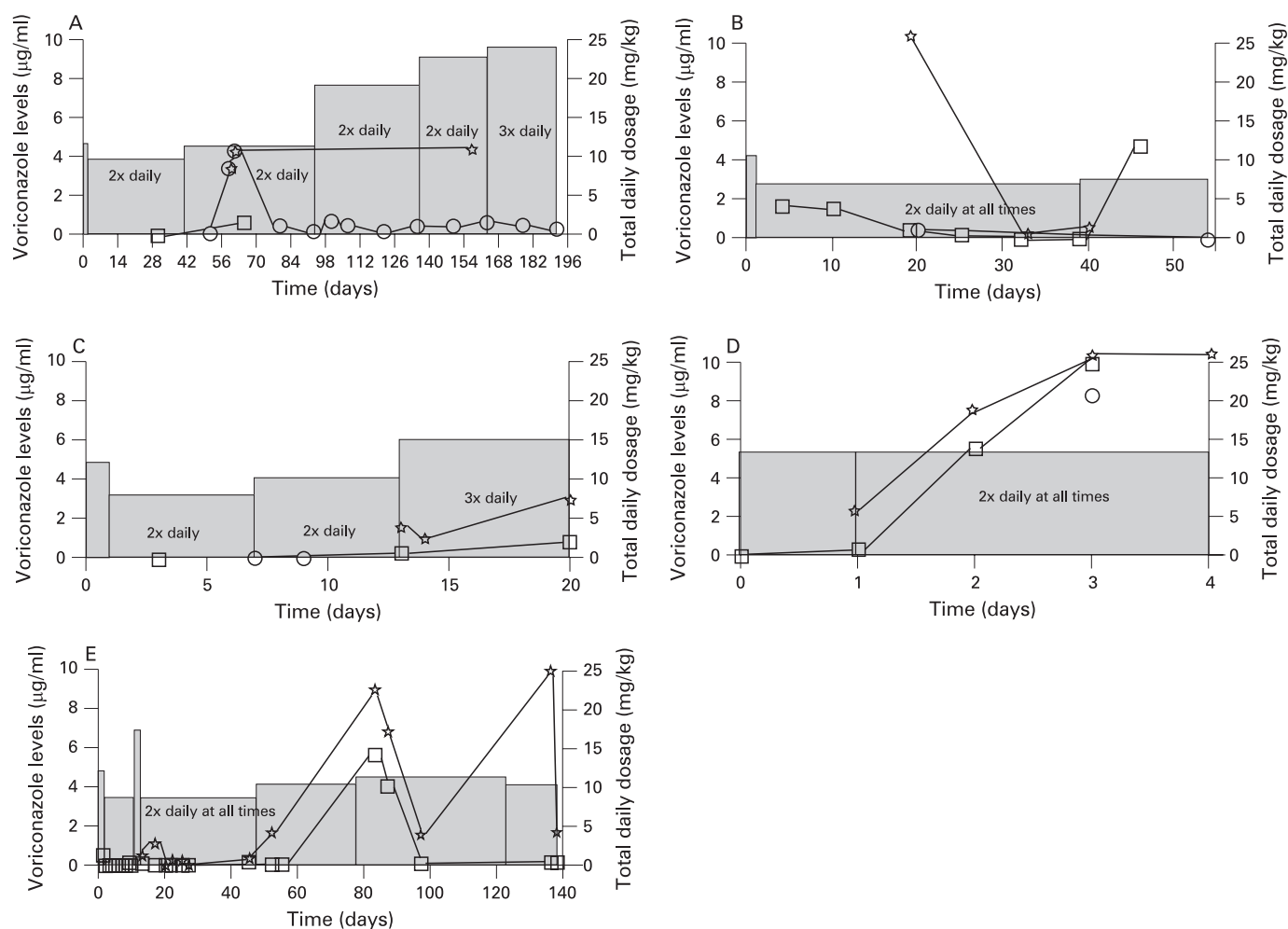
## RESULTS

Table 1 summarises the clinical findings from the five paediatric patients studied (three patients with leukaemia and two patients with burns). Voriconazole levels and dose adjustments for these patients are presented in fig 1.

## DISCUSSION

Voriconazole is known to have variable pharmacokinetics. In adults, steady-state plasma levels after 3–6 mg/kg twice daily intravenous infusion range from 3–6 µg/ml. Steady-state concentrations are achieved after 5–6 days (shorter if a loading dose is given). After 200 mg twice daily orally in adults, steady-state plasma concentrations generally range from 2–3 µg/ml.<sup>3</sup> However, in a study of voriconazole for the treatment of invasive aspergillosis, patients on standard doses demonstrated levels in plasma ranging from <0.1 µg/ml to as high as 9.7 µg/ml.<sup>2</sup> Studies in adults revealed nonlinear pharmacokinetics, which are thought to be related to saturation of metabolism, resulting in a ~threefold increase in the area under the curve (AUC<sub>T</sub>) following a 33% increase in dosage.<sup>3</sup> Thus, there is substantial inter-subject variability in the plasma concentrations achieved, especially in patients suffering from drug–drug interactions. CYP2C19, the major isozyme implicated in the metabolism of voriconazole, exhibits greater genetic polymorphism. As a result of a point mutation in the respective gene, some people are poor metabolisers, while some others are rapid metabolisers. Up to 7% of whites and ~20% of non-Indian Asians have a deficiency in the expression of this enzyme. The observed interpatient variability in voriconazole levels is ~100-fold,<sup>2</sup> and we are not aware of any other anti-infective agent with a similarly profile.

Unlike the findings in adults, studies have revealed that voriconazole undergoes linear pharmacokinetics in children. Paediatric patients have a higher capacity for elimination of voriconazole per kg of body weight than do adult healthy volunteers, and dosages of 4 mg/kg may be required in children to achieve exposures consistent with those in adults following dosages of 3 mg/kg.<sup>4</sup> Preliminary evidence suggests that the mean AUC<sub>T</sub> associated with a dose of 8 mg/kg taken intravenously in children approaches that seen with 4 mg/kg in adults.<sup>5</sup> In Europe, recommended dosage of intravenous voriconazole in 2–11-year-old



**Figure 1** Voriconazole levels for individual patients included in the study. Voriconazole trough levels are represented by squares. Stars represent peak levels and circles random levels. The boxes' height indicate voriconazole total daily dosage, the first box showing the loading dose. Frequency of voriconazole administration is also indicated.

patients is 7 mg/kg every 12 h, and no loading dose is recommended. Recommended oral maintenance dosage for these paediatric patients is 200 mg every 12 h. Because of the assumed limited gastrointestinal transit time, oral suspension should be preferred to the tablet formulation. There are no formal recommendations so far for the use of voriconazole in children in the United States.<sup>6</sup>

Given the relative unpredictability of voriconazole levels, measurement of plasma concentrations to identify extreme levels is warranted. In a previous study, patients with invasive aspergillosis who failed to demonstrate random levels  $>0.25 \mu\text{g/ml}$  had a higher probability of treatment failure.<sup>2</sup> These findings were also confirmed in a recent study, which showed a significant relationship between disease progression and drug

**Table 1** Summary of patients' characteristics

Case	1	2	3	4	5
Underlying diseases	ALL translocation (1;19) Schedule B	T-cell ALL Normal karyotype Schedule C	Severe burn injuries; multiple debridements	Severe burn injuries; multiple debridements	Acute myelocytic leukaemia M5
Disease presentation	Left paraspinal lump while on the maintenance phase	Left hemiparesis on day 34 after chemotherapy	Wound infection, sepsis	Seizures, severe encephalopathy	Sinusitis, orbital cellulitis and proptosis
Diagnosis	<i>Aspergillus fumigatus</i> abscess on the back. Later CNS aspergillosis	CNS aspergillosis caused by <i>A. fumigatus</i>	Probable <i>Aspergillus</i> invasive skin graft infection	Invasive cutaneous aspergillosis	Invasive sinusitis caused by <i>A. fumigatus</i>
Concomitant drugs*	Vincristine	Ambisome, Caspofungin	Caspofungin	Phenobarbitone (previous week), Midazolam	None
Outcome	Voriconazole failed to contain CNS infection (replaced by caspofungin and posaconazole). Clinically stable (followed by 27 months)	Died in 6 months. Positive PCR test for <i>Aspergillus</i> in the CSF just before death	Died within 1.5 month	Died in 8 days	Clinically stable (followed by 140 months)

ALL, acute lymphoblastic leukaemia; CNS, central nervous system, PCR, polymerase chain reaction; CSF, cerebrospinal fluid. \*Only drugs taken concomitantly with voriconazole were listed here. Apart from systemic antifungal drugs, only medications that could potentially cause drug interaction with voriconazole were listed. Each case is posted at [www.aspergillus.org.uk](http://www.aspergillus.org.uk) as case histories.

concentration ( $p < 0.025$ ).<sup>7</sup> A positive clinical response was observed in 100% (10/10) of patients with random voriconazole concentrations of above 2.05 µg/ml, whereas the disease progressed (and patients died) in eight out of 18 patients with concentrations below that level.<sup>8</sup> It may be that these are useful threshold trough concentrations. However, more data are required on this point, particularly in challenging situations such as cerebral infections. In addition, patients with plasma concentrations  $> 6$  µg/ml may be at risk for concentration-related toxicities,<sup>2</sup> including neurological adverse events.<sup>7</sup>

Only a few studies have reported the use of voriconazole levels to monitor therapy in children.<sup>9–11</sup> In one of the studies,<sup>9</sup> the introduction of phenobarbitone promoted a decrease in voriconazole peak concentration by ~50%. The premature patient described by Muldrew *et al* also required elevated voriconazole dosages (6 mg/kg every 8 h) owing to concomitant therapy with phenobarbitone.<sup>10</sup> In the report by Destino and colleagues, dosages as high as 13.4 mg/kg every 12 h were required to obtain trough concentrations of 0.2 µg/ml.<sup>11</sup> Similarly, Walsh *et al.*<sup>12</sup> showed that median plasma concentrations in children receiving dosages of  $\geq 4$  mg/kg per 12 h (1.6 µg/ml) were lower than those of adult volunteers receiving 4 and 5 mg/kg per 12 h (5.7 µg/ml and 7.4 µg/ml, respectively). Thus clearance of voriconazole is greater in children than in adults. Eiden *et al* reported that *torsades de pointes* occurred in a 14-year-old girl with high plasma trough levels (7 µg/ml).<sup>13</sup> The patient was also being treated with omeprazole, which is known to increase voriconazole  $C_{max}$  and  $AUC_T$  by 15% and 41%, respectively. *Torsades de pointes* had previously been described in a 15-year-old patient with normal voriconazole levels, suggesting that this rare adverse effect does not solely depend on voriconazole drug concentrations.<sup>14</sup> In both reported cases, genotyping of CYP2C19 (and 2C9) revealed no mutations, indicating that these patients were standard metabolisers.

In this case series we demonstrate how unpredictable voriconazole levels can be in children. For instance, patient 1 had levels frequently below the therapeutic target despite the use of voriconazole dosages as high as 8.1 mg/kg three times a day (a dosage much higher than that recommended for children). Patient 1 was also receiving vincristine — apparently, voriconazole levels are not affected by the use of vinca alkaloids, although vincristine may be increased to toxic concentrations.<sup>6</sup> Patients 2 and 5 received lower than currently recommended dosages of voriconazole — curiously, a marked increase in voriconazole trough levels was observed for these two patients after a small change in dosage. The occurrence of repeated low levels in patients 3 shows how much drug is required in some children to reach detectable concentrations. Burn injury may lead to accelerated azole clearance as demonstrated for fluconazole.<sup>15</sup> It remains to be elucidated whether higher voriconazole dosage is required for burn patients. Increased voriconazole clearance probably affected patient 4, also a patient with burns, who had low plasma levels despite the use of the recommended voriconazole dosage (7 mg/kg twice daily). This situation was probably aggravated by a drug interaction with phenobarbitone, which also accelerates clearance. Although stopped 1 week before voriconazole was started, this long-acting barbiturate is known to be a potent CYP450 inducer. Renal failure may have prolonged phenobarbitone's half-life in this patient. As could have been anticipated, voriconazole trough concentrations markedly increased over the following days despite no change in dosage, which is probably related to phenobarbitone induction wearing off, with a reduction in metabolism of voriconazole. Voriconazole has

### What is already known on this topic

- ▶ Voriconazole is an antifungal drug with marked inter-patient variation.
- ▶ Higher dosages of voriconazole are required to obtain the same plasma levels in children than in adults.

### What this study adds

- ▶ Appropriate voriconazole plasma levels are difficult to obtain in children, and marked intra-patient variability in these levels occurs.
- ▶ Optimal voriconazole dosage will probably require adjustments on an individual basis.

been shown to inhibit midazolam metabolism in vitro, apparently with no effect on voriconazole levels.<sup>6</sup>

In conclusion, while the optimal dose of voriconazole in children is unknown, monitoring plasma levels may be helpful to at least ascertain a minimal level of exposure, especially in patients concomitantly receiving other drugs that may interfere with voriconazole metabolism. Although trough levels are preferred, random/peak levels can also provide useful information if levels are extremes. Unfortunately, the limited number of patients included in this series does not allow us to define target voriconazole concentrations for children. Furthermore, it should be noted that no study has defined voriconazole exposure or levels that can predict clinical success or failure in children. As discussed in this article, to achieve measurable plasma concentrations similar to those in adults, paediatric patients may require higher doses of voriconazole or the administration of the drug at shorter intervals. Owing to the huge variability observed in patients' levels, the use of fixed doses of voriconazole is probably incorrect for both adults and children. Guidelines about dose modification for patients with very low or high plasma concentrations also need to be developed and validated.

**Funding:** ACP receives a grant from CAPES (Brazilian government).

**Competing interests:** In the past 5 years, DWD has received grant support from Astellas, Merck, Pfizer, F2G, OrthoBiotech, Indevus, Basilea, the Fungal Research Trust, the Wellcome Trust, the Moulton Trust, The Medical Research Council, the National Institute of Allergy and Infectious Diseases and the European Union. He has been an advisor/consultant to Basilea, Vicuron (now Pfizer), Schering Plough, Indevus, F2G, Nektar, Daiichi, Sigma Tau, Astellas, Gilead and York Pharma. He has been paid for talks on behalf of Astellas, Merck, GSK, Chiron, AstraZenca and Pfizer. He holds founder shares in F2G Ltd and Myconostica Ltd, both university spin-out companies. Myconostica is engaged in commercialising molecular diagnostics for infectious diseases, including invasive fungal infections.

### REFERENCES

1. Keevil BG, Newman S, Lockhart S, *et al.* Validation of an assay for voriconazole in serum samples using liquid chromatography-tandem mass spectrometry. *Ther Drug Monit* 2004;**26**:650–7.
2. Denning DW, Ribaud P, Milpied N, *et al.* Efficacy and safety of voriconazole in the treatment of acute invasive aspergillosis. *Clin Infect Dis* 2002;**34**:563–71.
3. Lazarus HM, Blumer JL, Yanovich S, *et al.* Safety and pharmacokinetics of oral voriconazole in patients at risk of fungal infection: a dose escalation study. *J Clin Pharmacol* 2002;**42**:395–402.
4. Walsh TJ, Karlsson MO, Driscoll T, *et al.* Pharmacokinetics and safety of intravenous voriconazole in children after single- or multiple-dose administration. *Antimicrob Agents Chemother* 2004;**48**:2166–72.
5. Walsh TJ, Driscoll TA, Arietta AC, *et al.* Pharmacokinetics, safety, and tolerability of voriconazole in hospitalized children. *46th Interscience Conference on Antimicrobial*

- Agents and Chemotherapy (ICAAC)*. San Francisco: American Society for Microbiology; 2006: Abstract M-887.
- Pfizer**. VFEND® IV (voriconazole) for injection, VFEND tablets, VFEND for oral suspension. [http://www.pfizer.com/pfizer/download/uspi\\_vfend.pdf](http://www.pfizer.com/pfizer/download/uspi_vfend.pdf) (accessed 25 January 2008).
  - Imhof A**, Schaer D, Schanz U, *et al*. Neurological adverse events to voriconazole: evidence for therapeutic drug monitoring. *Swiss Med Wkly* 2006;**136**:739–42.
  - Smith J**, Safdar N, Knasinski V, *et al*. Voriconazole therapeutic drug monitoring. *Antimicrob Agents Chemother* 2006;**50**:1570–2.
  - Maples HD**, Stowe CD, Saccente SL, *et al*. Voriconazole serum concentrations in an infant treated for *Trichosporon beigellii* infection. *Pediatr Infect Dis J* 2003;**22**:1022–4.
  - Muldrew KM**, Maples HD, Stowe CD, *et al*. Intravenous voriconazole therapy in a preterm infant. *Pharmacotherapy* 2005;**25**:893–8.

- Destino L**, Sutton DA, Helon AL, *et al*. Severe osteomyelitis caused by *Myceliophthora thermophila* after a pitchfork injury. *Ann Clin Microbiol Antimicrob* 2006;**5**:21.
- Walsh TJ**, Lutsar I, Driscoll T, *et al*. Voriconazole in the treatment of aspergillosis, scedosporiosis and other invasive fungal infections in children. *Pediatr Infect Dis J* 2002;**21**:240–8.
- Eiden C**, Peyrière H, Tichit R, *et al*. Inherited long QT syndrome revealed by antifungals drug–drug interaction. *J Clin Pharm Ther* 2007;**31**:321–4.
- Alkan Y**, Haefeli WE, Burhenne J, *et al*. Voriconazole-induced QT interval prolongation and ventricular tachycardia: a nonconcentration-dependent adverse effect. *Clin Infect Dis* 2004;**39**:e49–52.
- Boucher BA**, King SR, Wandschneider HL, *et al*. Fluconazole pharmacokinetics in burn patients. *Antimicrob Agents Chemother* 1998;**42**:930–3.

## Images in paediatrics

### Circumferential aortic dissection

An adolescent otherwise healthy male presented with acute onset chest pain. Physical examination was remarkable for early diastolic murmur of aortic regurgitation. Transthoracic and subsequently transoesophageal echocardiography revealed aortic dissection extending to the arch. CT angiography revealed a circumferential type of aortic dissection extending from the aortic root to the arch (type A) with extension of the dissection flap into the right brachiocephalic artery (fig 1).

#### DISCUSSION

The typical aortic dissection appears on contrast enhanced CT as an intimal flap that separates the false from the true lumen. Features indicative of a true lumen are outer wall calcification and eccentric flap calcification; beak sign, larger cross sectional area and slow enhancement are indicators of a false lumen.<sup>1–4</sup> In some instances, an atypical configuration of intimal flap is encountered. These include a calcified false lumen in chronic cases, an aorta with three or multiple channels, an extremely narrow true lumen, or rarely, as in the present case, a circumferential intimal flap.<sup>1,3</sup> The latter may be further complicated by intimo-intimal intussusception, although this was not evident in our case.<sup>5</sup>

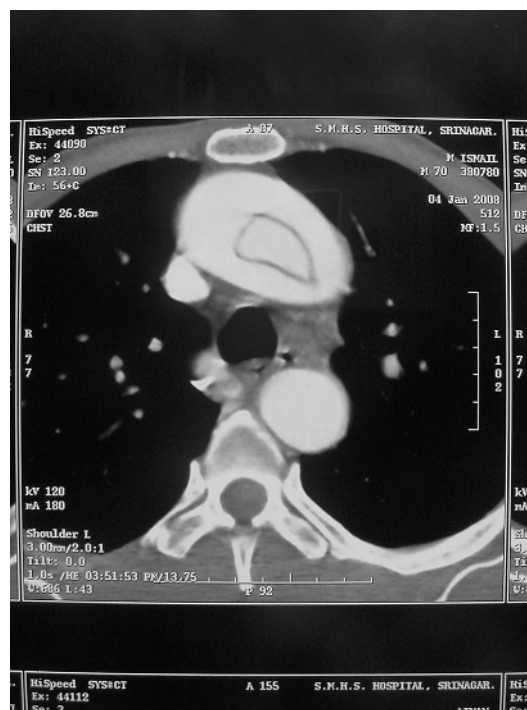
**N A Choh,<sup>1</sup> S A Choh,<sup>2</sup> B Naikoo,<sup>3</sup> S A Bhat,<sup>1</sup> M Jehangir<sup>1</sup>**

<sup>1</sup> Department of Radiology, SMHS Hospital, Srinagar, India; <sup>2</sup> Department of Pediatrics, SKIMS, Soura, Srinagar, India; <sup>3</sup> Department of Cardiology, SMHS Hospital, Srinagar, India

**Correspondence to:** Suhil A Choh, Department of Pediatrics, SKIMS, Soura, Srinagar, India; [suhilchoh@rediffmail.com](mailto:suhilchoh@rediffmail.com)

**Competing interests:** None.

*Arch Dis Child* 2008;**93**:581. doi:10.1136/adc.2008.139758



**Figure 1** Enhanced CT shows an intimal flap in the ascending aorta.

#### REFERENCES

- Sebastia C**, Pallisa E, Quiroga S, *et al*. Aortic dissection: diagnosis and follow-up with helical CT. *Radiographics* 1999;**19**(1):45–60.
- Pineiro DJ**, Bellido CA. Images in clinical medicine: circumferential dissection of the aorta. *N Engl J Med* 1999;**340**(20):1553.
- Lepage MA**, Quint LE, Sonnad SS, *et al*. Aortic dissection: CT features that distinguish true lumen from false lumen. *AJR Am J Roentgenol* 2001;**177**(1):207–11.
- Fisher ER**, Stern EJ, Godwin JD 2nd, *et al*. Acute aortic dissection: typical and atypical imaging features. *Radiographics* 1994;**14**(6):1263–71.
- Nelson KM**, Spizarny DL, Kastan DJ. Intimo-intimal intussusception in aortic dissection: CT diagnosis. *AJR Am J Roentgenol* 1994;**162**:813–14.

ADOS-G total scores and in the proportions regressing were small and entirely non-significant. The study still had power to detect a quite modest difference between cases and controls, of just one tenth of the range of normal variation: "Comparison of the combined case and control groups had 80% power to detect a mean titre difference of 45% (or 0.16 log<sub>10</sub>(mIU/ml)".<sup>1</sup>

The method of using peripheral blood mononuclear cells (PBMCs) as a proxy for gut mucosa has been employed in earlier studies<sup>2-5</sup> and by Dr Wakefield.<sup>6</sup> Measles virus replicates widely in immunologically active cells and if present in the gut mucosa, would be expected to be present in PMBC.

The proportion of children with regression (21%) is as expected from other studies and does include children whose parents date the onset of regression and autism to within 2 weeks of the MMR vaccination.

Further research into gastrointestinal symptoms in ASD is certainly needed. We have assessed (as described) a range of gastrointestinal symptoms in cases and controls (report in preparation) and many parents of children reported past vomiting, abdominal pain, diarrhoea and constipation (fewer reported current symptoms). We defined enterocolitis (the term used by Wakefield) as described, a definition familiar to paediatric gastroenterologists and replicable. Only one child in the control group had such a constellation of symptoms. A period of 14 days should be just long enough to exclude short term infections.

Dr Wakefield continues to assert a causative relationship between the MMR and autism. While no one study on its own can be considered absolute proof, the accumulated evidence of epidemiological and clinical studies, including our own, shows no plausible *causative* link between MMR and autism. More than a coincidence in timing is needed. Dr Wakefield's findings have not been independently confirmed. The d'Souza paper provides evidence of the "vulnerability of PCR technology to support claims of association" with high likelihood of false positives.<sup>2</sup> An alternative question that can be asked of proponents of the view put forward by Wakefield and colleagues is: "What is the scientific evidence of such a link?"

**Correspondence to:** Gillian Baird, Newcomen Centre, UMDS, Guy's Hospital, St. Thomas Street, London SE1 9RT, UK; [gillian.baird@gstt.nhs.uk](mailto:gillian.baird@gstt.nhs.uk)

**Competing interests:** None.

Accepted 1 July 2008

## REFERENCES

1. **Baird G**, Pickles A, Simonoff E, *et al*. Measles vaccination and antibody response in autism spectrum disorders. *Arch Dis Child* 2008;**93**:832-7.
2. **D'Souza Y**, Fombonne E, Ward BJ. No evidence of persisting measles virus in peripheral blood


mononuclear cells from children with autism spectrum disorder. *Pediatrics* 2006;**118**:1664-75.

3. **Singh VK**, Jensen RL. Elevated levels of measles antibodies in children with autism. *Pediatr Neurol* 2003;**28**:292-4.
4. **Baird G**, Simonoff E, Pickles A, *et al*. Prevalence of disorders of the autism spectrum in a population cohort of children in South Thames: the Special Needs and Autism Project (SNAP). *Lancet* 2006;**368**:210-15.
5. **Afzal MA**, Ozoemena LC, O'Hare A, *et al*. Absence of detectable measles virus genome sequence in blood of autistic children who have had their MMR vaccination during the routine childhood immunization schedule of U.K. *J Med Virol* 2006;**78**:623-30.
6. **Kawashima H**, Mori T, Kashiwagi Y, *et al*. Detection and sequencing of measles virus from peripheral mononuclear cells from patients with inflammatory bowel disease and autism. *Dig Dis Sci* 2000;**45**:723-9.

## BOOK REVIEW

### Ollie

Written by Stephen Venables. Published by Arrow Books Ltd, London, 2007, pp 400, £6.99 (paperback). ISBN: 10-0-09-947879-X



*Ollie* is a true account of a brave boy with autism who is later diagnosed with leukaemia. Ollie's father, Stephen Venables, is a fantastic and experienced writer who is able to draw in the reader. The book is an honest portrayal of the difficulties faced by a family when a

child is diagnosed with autism and subsequently leukaemia. It gives incredible insight into life with an autistic child, helping the reader imagine how the disorder takes over and dominates family life.

Frequently, trainees feel they have had very limited exposure to autism, their knowledge being based on the film *Rain man*. Reading this, I was able to empathise and see how a diagnosis of autism affects everyday family life. From a paediatric training perspective, it is much easier to understand and remember the key features of autism reading this book than a textbook. For example, it portrays what Ollie was like at nursery school – useful if you are asked to carry out a school visit. The book made me aware of the detail that families remember of encounters with the medical profession. For professionals, a patient may be one of many we see each day, whereas for the family, the encounter and its details are far more memorable. We read of how Ollie's family set out guidelines for staff regarding the way they would like Ollie to be treated. There are also many pages where hospital medicine is described from a family perspective, so acute paediatric trainees will also benefit. A well thought out index and bibliography provides

useful reference material for professionals, making it easy to refresh memories on different therapies.

The book describes in detail the pathway from parental concern to a diagnosis of autism and the various types of treatment. Many alternative therapies are discussed as Ollie's mother Rosie tries desperately hard to find anything that might help, including dietary supplementation as well as restriction. The education process is covered well, and a description of a battle with the local education authority is included. I learnt many things about alternative therapies and how Ollie's family felt. Discussions of different therapies are fairly balanced, as the family weigh up the benefits and disadvantages of each, as well as acknowledging the medical profession's scepticism on occasion. The Lovaas method, which often is not covered in conventional community paediatric textbooks, is described as part of the narrative. The author has woven explanations of different techniques into Ollie's story, maintaining a balance of opinions with accounts of why and how Ollie's parents chose techniques they thought would help him.

However, this book comes with a caution. Many of the controversies surrounding autism are discussed, and although opinions are given equal weight, the book cannot be used as medical fact. For example, Ollie was described as having an "overall pattern of reduced health" immediately following his MMR, and it is stated that "perhaps... the combined vaccine at fifteen months did lasting damage".

I would not recommend this book to parents of autistic children when the diagnosis is first made as it is almost too raw and tragic, especially in light of Ollie's subsequent death from leukaemia. However, I would strongly recommend this book to all paediatric trainees and consultants, regardless of whether they are based in the community or not. I hope those that read it will be inspired to reflect upon how their interactions with families are seen by the families themselves.

**A Raykundalia**

Surrey PCT, UK; [anu\\_morjaria@hotmail.com](mailto:anu_morjaria@hotmail.com)

## CORRECTION

doi:10.1136/adc.2007.118844corr1

A C Pasqualotto, *et al*. Voriconazole plasma monitoring. *Arch Dis Child* 2008;**93**:578-81. The last sentence of the results section of the abstract should read "Phenobarbitone caused important drug interactions with voriconazole for one of the patients".



## Voriconazole plasma monitoring

A C Pasqualotto, M Shah, R Wynn, et al.

*Arch Dis Child* 2008 93: 578-581 originally published online February 5, 2008

doi: 10.1136/adc.2007.118844

---

Updated information and services can be found at:

<http://adc.bmj.com/content/93/7/578.full.html>

---

### Data Supplement

*These include:*

"erratum"

<http://adc.bmj.com/content/suppl/2008/08/05/adc.2007.118844.DC1.html>

### References

This article cites 13 articles, 6 of which can be accessed free at:

<http://adc.bmj.com/content/93/7/578.full.html#ref-list-1>

Article cited in:

<http://adc.bmj.com/content/93/7/578.full.html#related-urls>

### Email alerting service

Receive free email alerts when new articles cite this article. Sign up in the box at the top right corner of the online article.

---

### Topic Collections

Articles on similar topics can be found in the following collections

[Drugs: infectious diseases](#) (462 articles)

[Unwanted effects / adverse reactions](#) (60 articles)

[Medicines regulation](#) (37 articles)

[Oncology](#) (419 articles)

---

### Notes

---

To request permissions go to:

<http://group.bmj.com/group/rights-licensing/permissions>

To order reprints go to:

<http://journals.bmj.com/cgi/reprintform>

To subscribe to BMJ go to:

<http://group.bmj.com/subscribe/>