

## CYCLOSPORIN A IN PATIENTS RECEIVING RENAL ALLOGRAFTS FROM CADAVER DONORS

R. Y. CALNE  
S. THIRU  
P. McMASTER  
G. N. CRADDOCK  
D. J. G. WHITE  
D. B. EVANS  
D. C. DUNN  
B. D. PENTLOW  
KEITH ROLLES

*Departments of Surgery and Pathology, University of Cambridge; and Dialysis Unit, Addenbrooke's Hospital, Cambridge*

**Summary** Seven patients on dialysis with renal failure received transplants from mismatched cadaver donors and were treated with cyclosporin A (CyA), initially as the sole immunosuppressive agent. CyA was effective in inhibiting rejection but there was clear evidence of both nephrotoxicity and hepatotoxicity. A cyclophosphamide analogue was added to the CyA treatment in six of the patients. Five patients are out of hospital with functioning allografts, and two of these have received no steroids. One patient required an allograft nephrectomy because of pyelonephritis in the graft. Another died of systemic aspergillus and candida infection. Further careful study of this potentially valuable drug will be required before it can be recommended in clinical practice.

### Introduction

MOST transplant clinicians find corticosteroids essential in the prevention of organ-graft rejection, but they have many unwanted effects, and their replacement by safer and more effective chemical immunosuppressants is desirable. A peptide fungal metabolite, cyclosporin A (CyA), has been found to prolong survival of skin grafts in mice,<sup>1</sup> of heterotopic cardiac allografts in rats,<sup>2</sup> of renal allografts in mongrel dogs,<sup>3</sup> and of orthotopic heart grafts in pigs.<sup>4</sup> In dogs given CyA both survival and allograft function were better than in those treated with azathioprine. Rejection and infection were less, and marrow depression was not seen. Since our earlier report,<sup>4</sup> pigs with orthotopic allografts fared well. 3 of 8 have died at days 22, 43, and 72. In the remaining 5 CyA was stopped after 125–197 days, and they remain alive with a median survival in excess of 180 days. In pigs the drug had no obvious side-effects, but 5 (14%) of the 34 dogs with renal allografts became jaundiced.<sup>5</sup> At necropsy 1 proved to have toxoplasmosis in the liver. The other jaundiced animals had areas of focal liver-cell necrosis and cholestasis. 12 (35%) of the dogs died of in-

fection, mostly in the lungs, and 8 (23%) died of rejection, 4 of these being animals in which CyA was stopped 11–14 days after transplantation.

CyA has been studied in two other species with renal allografts—the rhesus monkey (our unpublished observations) and the rabbit.<sup>6,7</sup> In both these species it was powerfully immunosuppressive without obvious side-effects. We felt that the experimental background justified a pilot study of CyA, as the sole immunosuppressant initially, in patients with first cadaveric renal allografts from mismatched donors.

### Materials and Methods

CyA was started on the day of grafting, injected intramuscularly dissolved in 'Miglyol' 25 mg/kg for the first 2 to 3 days, until the patients could take the drug orally, dissolved in olive oil, at the same dosage. In two cases the preparation of CyA was changed from olive oil to Sandoz capsules in the third postoperative month. Details of the patients are in table 1. The drug dosage in mg/kg was the same as that which achieved good immunosuppressive results with few side-effects in pigs with cardiac allografts and dogs and rabbits with renal allografts. All the kidneys came from donors with complete irreversible cerebral destruction but with intact circulations maintained on mechanical ventilation during nephrectomy. There was therefore no more than a few minutes during which the kidneys were warm and ischaemic. The organs were preserved by flush cooling and ice storage.<sup>8</sup> They were cold and ischaemic for between 1.25 and 16 hours. Liver and renal function were carefully monitored postoperatively and full blood-counts were done daily. In no case could the kidney be regarded as well-matched: all were incompatible for two or more of the four HLA-A, B antigens. The T-cell proliferative responses of peripheral-blood lymphocytes were assessed weekly. Serum samples were studied for their ability to inhibit phytohaemagglutinin (P.H.A.) responses of lymphocytes from normal individuals. Biopsy specimens were taken from six of seven allografts and examined by light microscopy. Two of these had immunofluorescence studies and one was examined by electron microscopy.

### Results

None of the biopsy specimens showed severe or extensive mononuclear-cell infiltration of the interstitium, interstitial haemorrhage, or other histological evidence of severe rejection. When the infiltrating mononuclear cells were sparse and focal a mild cellular rejection reaction was diagnosed. When numbers of cells were increased or the infiltration more diffuse this was regarded as moderate rejection and these cases often had accompanying interstitial oedema (table II). Foci of proximal tubular epithelial degenerations were present in some biopsy

specimens. Hæmorrhagic necrosis of a glomerulus was present in case 3, with fibrin deposition in arterial and arteriolar walls (fig. 1). Immunofluorescence studies were done on cases 4 and 7, and the tissues were examined with antisera for IgG, IgM, IgA, C<sub>3</sub>, C<sub>1</sub>q, and fibrinogen; the results are in the case-histories.

Electron microscopy of biopsy tissue from case 7 (on

day 14) showed normal glomerular structure and no evidence of basement-membrane abnormality. There was interstitial œdema, and foci of proximal tubular cells showed degeneration with damaged microvilli, dissolution of mitochondria, and increase in phagosomes. No abnormal deposits were visible on tubular basement membranes.

TABLE I—CLINICAL DETAILS

| Diagnosis                       | No. of HLA-AB mismatches | Previous bilateral nephrectomy | Total ischæmia (min) | Previous blood-transfusions (in units) | Daily dose in mg/kg<br>(CM=cytimun; P=prednisoline;<br>d=day)  | Outcome  |
|---------------------------------|--------------------------|--------------------------------|----------------------|--|--|--|
| 1. Glomerulonephritis           | 2                        | No                             | 958                  | 20 in preceding<br>18 mo               | Cy A. 25 d0-11<br>20 d 12-14<br>17 d 15-21<br>12 d 22-27   | Transplant nephrectomy<br>day 28. Pyelonephritis in<br>graft. On dialysis. |
| 2. Systemic lupus erythematosus | 3                        | No                             | 514                  | 9 in preceding<br>18 mo                | Cy A. 25 d0-12<br>20 d 13-15<br>15 d 16-18<br>10 d 18 continuing   | Discharged on day 22.  |
| 3. Malignant hypertension       | 4                        | Yes                            | 348                  | 4 in preceding<br>4 mo                 | Cy A. 25 d0-15<br>20 d 16-17<br>17 d 18-36<br>12 d 37<br>continuing<br>CM 2.0 d 10-28<br>1.5 d 29-30<br>1.0 d 31-36<br>0.5 d 37<br>continuing  | Vascular rejection day 7.<br>Recovered function.<br>Discharged day 53.     |
| 4. Glomerulonephritis           | 3                        | No                             | 583                  | 5 in preceding<br>4 mo                 | Cy A. 25 d0-13<br>20 d 14-23<br>17 d 24-31<br>12 d 32-37<br>17 d 38-46<br>12 d 61<br>continuing as<br>capsules from<br>64th day<br>CM 2.0 d 47-49<br>1.0 d 56<br>continuing<br>P. 4.0 d 49-51<br>2.0 d 52<br>1.0 d 53-54<br>0.7-0.5 d 56-60<br>0.4 d 61-81<br>0.2 d 82<br>continuing             | Discharged day 42.   |
| 5. Chronic pyelonephritis       | 3                        | Yes                            | 368                  | 4 in preceding<br>2 mo                 | Cy A. 25 d0-16<br>20 d 17-24<br>15 d 25-32<br>10 d 33-37<br>20 d 38-44<br>15 d 45-66<br>10 d 67-68<br>12 d 69 as<br>capsules<br>continuing<br>CM 1.0 d 50<br>continuing<br>P. 4.0 d 42-44<br>2.0 d 45<br>1.0 d 46<br>0.5-0.1 d 47-53<br>0.4 d 54-66<br>0.3-0.2 d 67-72<br>0.1 d 73<br>continuing | Discharged day 78.   |
| 6. Malignant hypertension       | 2                        | No                             | 215                  | 3 in preceding<br>3 mo                 | Cy A. 25 d0-5<br>20 d 6-11<br>15 d 12-13<br>10 d 14-18<br>25 d 19-24<br>20 d 25-45<br>15 d 46<br>continuing<br>CM 1.0 d 71<br>continuing<br>P. 4.0 d 21-23<br>2.0 d 24<br>1.0 d 25<br>0.5 d 26-40<br>0.4 d 41-48<br>0.3 d 49-51<br>0.2 d 52<br>continuing  | Discharged day 56.   |
| 7. Malignant hypertension       | 2                        | No                             | 75                   | 3 in preceding<br>3 mo                 | Cy A. 25 d0-4<br>22 d 5-6<br>19 d 7-9<br>16 d 10-11<br>13 d 12-13<br>9 d 14-18<br>25 d 19-24<br>19 d 25-38<br>16 d 39-43<br>13 d 44-45<br>CM 2.0 d 41-43<br>1.0 d 44-45<br>P. 4.0 d 21-23<br>2.0 d 24<br>1.0 d 25<br>0.5 d 26-40<br>0.4 d 41-42<br>0.2 d 43<br>continued<br>until death          | Died day 55,<br>disseminated aspergillosis                                 |

TABLE II—LIGHT MICROSCOPY IN SIX CASES

| Abnormalities   | No.                      |
|---|--------------------------|
| Degeneration and vacuolation of proximal tubular epithelium | 2 (cases 1 and 5)        |
| Acute tubular necrosis                                      | 4 (cases 3, 4,* 6 and 7) |
| Cellular infiltrate:  |                          |
| None  | 1 (case 4†)              |
| Slight  | 3 (cases 3, 5 and 6)     |
| Moderate  | 3 (cases 1, 4,* and 7)   |
| Interstitial oedema   | 3 (cases 1, 4,* and 7)   |
| Vasculitis  | 1 (case 3)               |

\*2nd biopsy

†1st biopsy

### Case 1

This patient of 38 had a history of myocardial infarction and had been treated with anticoagulants before surgery. Urine output was 2.2 l in the first 24 hours after operation and 0.8 l in the second 24 hours; then he became anuric. X-ray of the ureter via the in-situ ureteric catheter showed blood clot in the renal pelvis and the kidney was explored on the seventh day. The ureter was reimplanted into the bladder after removal of the blood-clot and a nephrostomy was performed. A biopsy specimen showed mild interstitial oedema and moderate cellular rejection. Oliguria persisted. One month after operation the urine was infected and he was pyrexial. The transplant was removed and showed acute pyelonephritis and parenchymal haemorrhage. The patient is now on dialysis.

### Case 2

A woman of 30 had allograft function from the time of operation. She was discharged from hospital after three weeks. 3½ months after operation she is in good health with a serum-creatinine between 150 and 160 µmol/l and a creatinine clearance of 45 ml/min. Facial and limb hair increased slightly one month after transplantation, but this has not progressed.

### Case 3

A 21-year-old man passed 500 ml of urine in the first 24 hours after operation. Output then steadily declined. After a week he was anuric, and biopsy (fig. 1) revealed deposition of fibrin in the walls of small arteries and haemorrhagic necrosis of a glomerular tuft with the arteriole at the vascular pole showing a focus of fibrinoid necrosis. There was a mild perivascular mononuclear-cell infiltrate of the interstitium and some proximal tubular necrosis. 'Cytimun' (ASTA5122) a cyclophosphamide derivative, was started on the 10th day at 2 mg/kg. The patient required haemodialysis four times after operation and then his urine output slowly increased. On the 19th postoperative day he passed a litre of urine. 5 days later the serum-creatinine started to fall and he required no further dialysis. 30 days after operation the cytimun dose was dropped to 1 mg/kg and 6 days later CyA was reduced to 12 mg/kg. He was discharged from hospital 2 months after operation and 3½ months after operation he is in good health with serum-creatinine of 200 µmol/l and creatinine clearance 43 ml/min. Treatment continues with 12 mg/kg of CyA and 0.5 mg/kg of cytimun.

### Case 4

A 27-year-old Nepalese man had allograft function immediately and passed 2½ l of urine on the 3rd postoperative day. 2 days later urine output fell and the serum-creatinine rose. A renal-biopsy specimen showed no abnormality on light microscopy. On immunofluorescence examination there was diffuse linear staining for fibrinogen, IgG on tubular basement membrane, and focal staining of the glomerular basement mem-

brane. Therapy was not changed; renal function continued to deteriorate for 4 days and then slowly improved. He was discharged from hospital on the 42nd postoperative day and was admitted one week later with jaundice and a serum-bilirubin of 68 µmol/l, alkaline phosphatase 166 U/l, and serum-glutamic-pyruvic-transaminase (S.G.P.T.) 45 U/l. CyA was withdrawn and he was started on cytimun 2 mg/kg for 3 days and then prednisolone 4 mg/kg/day tailing off after 3 days to 1 mg/kg. After one week cytimun was restarted, 1 mg/kg/day. During this time the jaundice rapidly resolved. A liver-biopsy specimen showed numerous mitoses of hepatocytes and one cytomegalovirus inclusion body. There were areas of focal parenchymal necrosis. A second allograft biopsy specimen showed small foci of acute tubular necrosis, interstitial oedema, and a moderate cellular rejection reaction. CyA treatment was reintroduced and the patient was discharged from hospital again on the 21st postoperative day. 3 months after operation he is in good health with serum-creatinine of 150 µmol/l and creatinine clearance of 53 ml/min, on treatment with CyA 10 mg/kg (which has just been changed to capsule form), cytimun 1 mg/kg, and prednisolone 0.2 mg/kg.

### Case 5

In this woman of 22 the allograft functioned immediately. After one week the serum-creatinine had fallen from 960 to 200 µmol/l but renal function slowly deteriorated and on the 36th postoperative day the serum-creatinine was 414 µmol/l. On exploration the kidney looked normal. A biopsy specimen

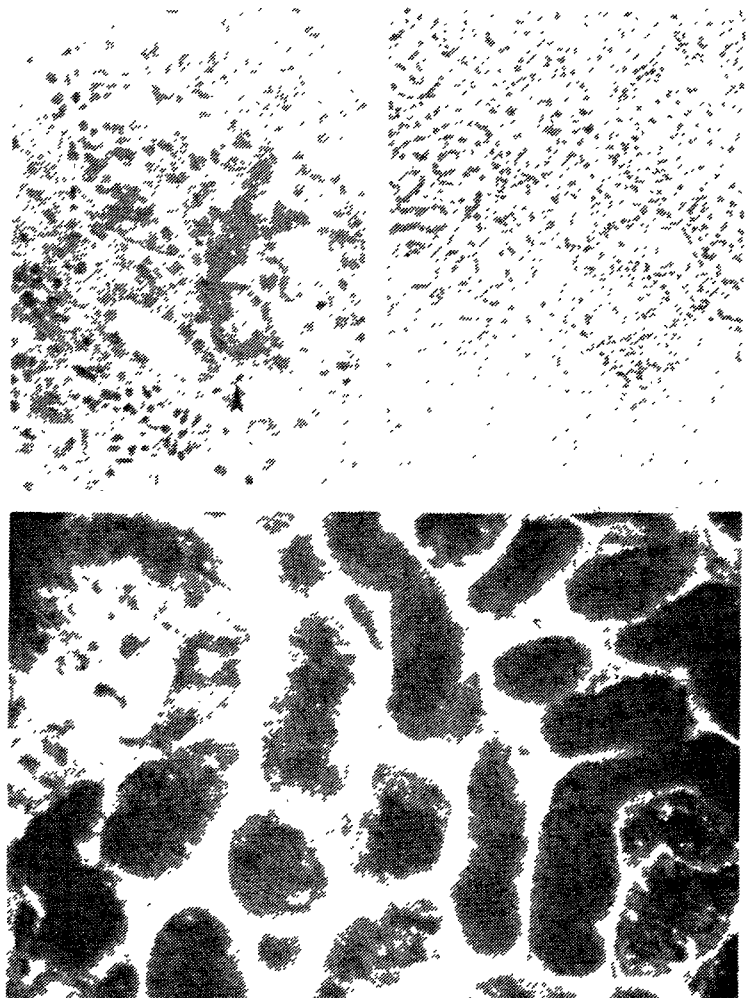


Fig. 1—Haemorrhagic necrosis of glomerular tuft (case 3).

Arrow points to vascular pole, showing fibrinoid necrosis.

Fig. 2—Biopsy specimen from case 7.

Fig. 3—Immunofluorescence micrograph case 7.

showed fine vacuolation of proximal tubular cells and a mild cellular rejection reaction. There was no interstitial oedema or vasculitis. CyA had been reduced after four weeks to 10 mg/kg. 42 days after operation prednisolone was started, at 5 mg/kg for 3 days and then rapidly tailed down. The CyA dose had been increased to 20 mg/kg for a week and then was dropped to 15 mg/kg. Renal function did not deteriorate further and there was a temporary slight improvement. 58 days after transplantation, the serum-creatinine was 474  $\mu\text{mol/l}$ . On day 59 cytimun was started at 1 mg/kg and renal function slowly improved. 69 days after operation the serum-creatinine was 300  $\mu\text{mol/l}$ , the prednisolone having been reduced to 0.2 mg/kg and the cytimun still at 1 mg/kg. The olive-oil preparation of CyA was changed to capsules. Renal function continued to improve and she was discharged from hospital on the 78th postoperative day. Now 3 months after operation she is in good health; her serum-creatinine is 340  $\mu\text{mol/l}$  and creatinine clearance is 28 ml/min. She receives daily 0.1 mg/kg of prednisolone, 1 mg of cytimun, and 15 mg/kg CyA in capsule form. A slight increase in facial and limb hair, noticeable after the first month, has not progressed.

### Case 6

In this man of 52 the allograft did not function after operation. A biopsy specimen taken on day 10 showed mild focal cellular infiltration and necrosis of a few tubules; oedema was absent. CyA dosage was dropped to between 10 and 15 mg/kg. On the 19th postoperative day it was increased to 25 mg/kg/day and 2 days later prednisolone was added at 4 mg/kg for 3 days, tailing off to 0.5 mg/kg/day after a week. On the 34th postoperative day, urine output had reached 1 litre and dialysis was no longer required. On the 56th postoperative day the patient was discharged from hospital with a serum-creatinine of 440  $\mu\text{mol/l}$  and a creatinine clearance of 22 ml/min. The prednisolone dose had been reduced to 0.2 mg/kg on the 52nd postoperative day and CyA had been reduced to 15 mg/kg on the 46th postoperative day. He is in good health but his renal function remains impaired.

### Case 7

In this man of 46 the allograft did not function after operation. A biopsy specimen taken on day 14 showed moderate cellular infiltration—the most severe cellular rejection in any of these patients (fig. 2). Immunofluorescence revealed almost diffuse linear staining of fibrinogen, with IgG on tubular basement membrane and focally on glomerular basement membrane (fig. 3). On the 21st postoperative day prednisolone was started, 4 mg/kg/day for 3 days dropping to 0.4 mg/kg/day after a further 2 days. On the 30th postoperative day the 24-hour urine output reached 1 litre. CyA dose had been dropped to 19 mg/kg; on the 42nd postoperative day cytimun was started, 2 mg/kg, and the prednisolone dosage was reduced over the next few days to 0.2 mg/kg. Since the patient was becoming generally unwell and had a swinging pyrexia, on the 46th day the cytimun and CyA were stopped and steroids were given to maintain the blood-pressure, which had fallen during septicæmic episodes. No focus of infection could be found and on the 51st day the kidney was explored. Frozen section of a biopsy specimen showed no evidence of infection, but there was tubular necrosis and acute hæmorrhagic necrosis of segments of several glomerular tufts, probably the result of septicæmia. The cellular infiltrate which had been seen in the previous biopsy specimen had disappeared. The kidney was removed but the patient died 6 days later and necropsy revealed disseminated aspergillosis and candidiasis. Histological examination of the nephrectomy specimen confirmed the frozen-section findings.

In all seven patients serum levels of bilirubin and alkaline phosphatase rose during the first week after operation. They remained increased while dosage of CyA

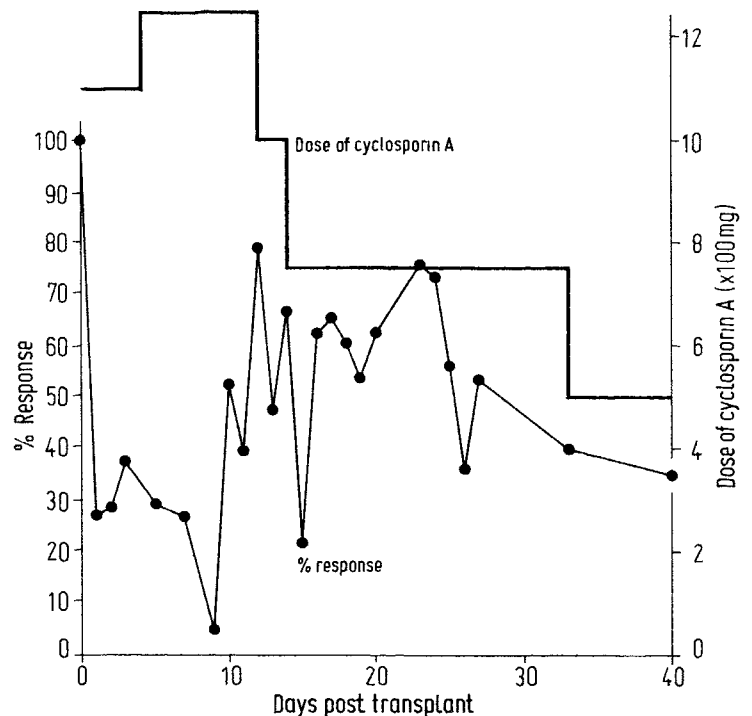


Fig. 4—Inhibition of P.H.A. mitogenesis by 10% serum from transplant recipient treated with CyA.

was 25 mg/kg daily, but fell slowly thereafter to normal. Only one patient (case 4) became clinically jaundiced and biopsy showed cytomegalovirus. Three patients (cases 2, 3, and 4) had transient increases of S.G.P.T.: the highest recorded was 84 u/l. The transaminase levels fell when the CyA was reduced.

There was no evidence of marrow toxicity in any patient. The peripheral white-blood-cell, total, and differential counts remained within normal limits and the hæmoglobin levels and red-cell counts in patients discharged from hospital continue to rise spontaneously.

Lymphocytes from patients treated with CyA were still capable of mounting mitogenic responses to P.H.A., concanavalin A, and staphylococcal protein A. Their ability to respond to donor stimulation in mixed lymphocyte culture was impaired. Sera from these patients taken after the start of CyA therapy, when added to P.H.A.-stimulated cultures of normal lymphocytes, were usually inhibitory. This inhibition was not affected by dialysis. Fig. 4 shows the P.H.A. response given by serial serum samples from case 2. This type of assay is the only means at present available for assessing blood-levels of CyA or its active components. It has not proved reliable since serum samples from patients and animals retaining functioning allografts and treated with CyA do not always depress these P.H.A. responses. The in-vitro studies will be reported in detail elsewhere.

### Discussion

This pilot study shows that CyA has a profound immunosuppressive effect in man, similar to that observed in various animals. The most severe cellular rejection diagnosed histologically was of only moderate degree and the appearances were typical of an immune reaction which can be readily reversed with steroid treatment. This degree of histological change has often been found in kidneys that were functioning normally. None of the patients had typical rejection crises with swollen allografts, pyrexia, and severe histological changes.

Three side-effects have been observed. Firstly, the slight increase in facial and limb hair observed in the two female patients does not seem to be a severe complication. Secondly, the hepatotoxicity seen in these patients has been mild and transient, but we have avoided adding other potentially hepatotoxic drugs such as azathioprine—hence the use of cytimun. (Cytimun seems to have a better therapeutic index as an immunosuppressant than cyclophosphamide, and we have used it with satisfactory results in some of our patients with liver grafts.<sup>9</sup>) We were pleased with the outcome in case 3, since severe focal vascular rejection usually indicates an extremely poor outlook.<sup>10</sup> Cytimun is believed to be more active against B cells than against T cells and may be especially valuable in antibody-mediated rejection.<sup>11</sup> Since CyA seems to act mainly on proliferating T cells, cytimun may prove a useful drug to combine with CyA. Thirdly, the nephrotoxicity: this is particularly worrying in a drug used for patients with renal allografts. None of our patients treated with CyA has normal function, although five are out of hospital without any symptoms of renal failure. It seems likely that CyA has direct toxic effect on renal tubules or on the blood-supply of the tubules and that patients vary in their susceptibility to these toxic reactions, though the nephrotoxicity is probably dose dependent.<sup>12</sup> The immunofluorescence findings in the tubular basement membrane in two of the patients could be non-specific. None of the patients seems to have antibodies against HLA antigens or renal tissue. Conceivably, however, CyA might act as a hapten attracting immunological damage to tubular basement membrane.

At present there is no direct way of measuring blood-levels of CyA and we therefore have no accurate information on its absorption when administered by different routes and in different solvents. It is insoluble in aqueous solutions but dissolves in oil and alcohol. When an oily solution is mixed with aqueous solution the compound precipitates. Whether this occurs in vivo and, if so, what are the biological consequences, remains to be seen.

The nephrotoxicity has made management of patients very difficult. We have probably added unnecessary and possibly harmful immunosuppressive agents in some patients, and perhaps persisted with too high a dosage of CyA in all. Although Green and Allison<sup>5</sup> report that two weeks' treatment with CyA is sufficient to maintain renal allografts in rabbits, this has not been our experience in dogs and we are therefore disinclined to stop the drug abruptly in patients. 5 pigs with cardiac allografts have had CyA stopped after 4–7 months without rejecting their allografts in the subsequent 1–2 months. Another animal treated for 63 days did reject its graft, dying 9 days after CyA was stopped. The mode of action of CyA seems different from that of other immunosuppressive agents; the drug lacks marrow toxicity and has no obvious steroid-like effects. Two of the patients out of hospital have never been treated with steroids; the remaining three are on a low dose of prednisolone which we will try to stop.

Further careful study of a limited number of patients is necessary before CyA can be recommended in clinical practice. We need to explore different dose schedules, different times of administration, and the possibility of combining CyA with other drugs that might prevent the nephrotoxicity.

We gratefully acknowledge the help of our medical, nursing, and technical colleagues in both the experimental and the clinical studies and of the Department of Medical Illustration, Addenbrooke's Hospital. We thank Sandoz Ltd (Basel) and Astawerke Gesellschaft (Bielefeld) for generous supplies of drugs.

Requests for reprints should be addressed to R.Y.C., Department of Surgery, Addenbrooke's Hospital, Cambridge CB2 2QQ.

#### REFERENCES

1. Borel, J. F., Feurer, C., Gubler, H. U., Stahelin, H. *Ag. Actions*, 1976, **6**, 468.
2. Kostakis, A. J., White, D. J. G., Calne, R. Y. *I.R.C.S. med. Sci.* 1977, **5**, 280.
3. Calne, R. Y., White, D. J. G. *ibid.* p. 595.
4. Calne, R. Y., White, D. J. G., Rolles, K., Smith, D. P., Herbertson, B. M. *Lancet*, 1978, *i*, 1183.
5. Calne, R. Y., et al. *Transplant. Proc.* (in the press).
6. Green, C. J., Allison, A. C. *Lancet*, 1978, *i*, 1182.
7. Dunn, D. C., White, D. J. G., Wade, J. *I.R.C.S. med. Sci.* 1978, **6**, 464.
8. Pentlow, B. D., Wall, W. J., Kostakis, A. J., Baker, P. G., Smith, D. P., Underwood, J., Calne, R. Y. *ibid.* 1976, **4**, 560.
9. Calne, R. Y. *Clin. exp. Immun.* (in the press).
10. Herbertson, B. M., Evans, D. B. *Histopathology*, 1977, **161**, 178.
11. Botzenhardt, U., Lemmel, E.-M. *Eur. J. Immun.* 1975, **5**, 667.
12. Powles, R. L., Barrett, A. J., Clink, H., Kay, H. E. M., Sloane, J., McElwain, T. J. *Lancet*, 1978, *ii*, 1327.

### CYCLOSPORIN A FOR THE TREATMENT OF GRAFT-VERSUS-HOST DISEASE IN MAN

R. L. POWLES  
H. CLINK  
J. SLOANE

A. J. BARRETT  
H. E. M. KAY  
T. J. McELWAIN

*Leukæmia Unit, Royal Marsden Hospital, and Divisions of Medicine and Tumour Immunology, Institute of Cancer Research, Sutton, Surrey*

**Summary** Cyclosporin A was given to five patients with acute leukæmia in whom graft-versus-host disease (G.V.H.D.) had developed after bone-marrow transplantation from sibling donors. In all instances the acute erythematous skin reaction of G.V.H.D. resolved within two days, but four of the five patients died. Cyclosporin A in high doses produced anorexia, nausea, and a reversible rise in blood-urea. The four patients who died all had liver damage, but the histological changes varied. Cyclosporin A modifies the acute skin reaction of G.V.H.D. In the management of liver and gut G.V.H.D., and in prophylaxis of G.V.H.D., its role needs to be determined.

#### Introduction

CYCLOSPORIN A is a new fungal cyclic polypeptide with great potential as an immunosuppressive agent in man. It specifically inhibits transforming lymphocytes and depresses hypersensitivity reactions and antibody production.<sup>1</sup> It can prevent organ and skin-graft rejection in animals,<sup>2,3</sup> and in rodents it can inhibit graft-versus-host disease (G.V.H.D.).<sup>4</sup> We report here a pilot study of cyclosporin A treatment in leukæmic patients with G.V.H.D. after marrow transplantation.

#### Patients

The five patients all received allogeneic bone-marrow transplants (clinical details in table 1). The donors were HLA-identical, mixed-lymphocyte-culture-compatible sibs. During transplantation they were nursed in reverse-