

## Acute invasive fungal rhinosinusitis: our experience with 18 cases

Mehdi Bakhshae<sup>1</sup> · Amin Bojdi<sup>2</sup> · Abolghasem Allahyari<sup>3</sup> · Mohammad Reza Majidi<sup>4</sup> · Sherwin Tavakol<sup>5</sup> · Mohammad Javad Najafzadeh<sup>6</sup> · Masoud Asghari<sup>7</sup>

Received: 10 January 2016 / Accepted: 18 May 2016  
© Springer-Verlag Berlin Heidelberg 2016

**Abstract** Acute invasive fungal rhinosinusitis (AIFRS) is a rapidly progressive life threatening infection that is seen most commonly among immunocompromised patients. We present a case series of 18 patients clinically and histopathologically diagnosed with AIFRS with a mean follow-up of  $9.11 \pm 2.51$  months (range 6–17). Demographic data, apparent symptoms and signs, underlying disorders, and outcomes are discussed. The mean age was  $39.56 \pm 20.66$  years (range 2–75). The most common underlying diseases were diabetes mellitus (50 %) and leukemia (44.44 %). Mucosal biopsy confirmed fungal invasion of the nasal mucosa in all cases. The main fungi were *Rhizopus oryzae* (55.56 %), *Abisidia mucor* (16.67 %), and *Aspergillus fumigatus* (27.78 %). Headache and facial pain (77.8 %), facial paresthesia (55.6 %), and ophthalmoplegia (33.3 %)

were the most common symptoms and signs. Computed tomography and endoscopic findings showed various stages of sinonasal (100 %), pterygopalatine fossa (55.56 %), orbital (44.45 %), and cerebral (5.56 %) involvement. All patients underwent serial surgical debridement ( $3.78 \pm 1.80$  times; range 2–8) simultaneously with systemic antifungal therapy and proper management of the underlying disease. The most extreme case with brain involvement survived and recovered with no evidence of recurrent disease following treatment. All patients were considered cured after two endoscopic negative histopathologic evaluations. Three patients (16.67 %) died, one from uncontrolled leukemia and two due to renal failure. AIFRS is a potentially fatal condition, however, early diagnosis and management of the underlying disease accompanied with

✉ Masoud Asghari  
masasghari58@bums.ac.ir; Masasghari58@gmail.com

Mehdi Bakhshae  
mehbakhsh@yahoo.com

Amin Bojdi  
Bojdya@mums.ac.ir

Abolghasem Allahyari  
Allahyari.abolghasem@yahoo.com

Mohammad Reza Majidi  
Majidi@mums.ac.ir

Sherwin Tavakol  
Sherwin.tavakol@gmail.com

Mohammad Javad Najafzadeh  
Najafzadehmj@mums.ac.ir

<sup>2</sup> Infectious Department, Faculty of Medicine, Mashhad University of Medical Sciences, Mashhad, Iran

<sup>3</sup> Hematology-Oncology Department, Faculty of Medicine, Mashhad University of Medical Sciences, Mashhad, Iran

<sup>4</sup> Otorhinolaryngology-Head and Neck Surgery, Faculty of Medicine, Mashhad University of Medical Sciences, Mashhad, Iran

<sup>5</sup> Mashhad University of Medical Sciences, Mashhad, Iran

<sup>6</sup> Medical Mycology, Faculty of Medicine, Mashhad University of Medical Sciences, Mashhad, Iran

<sup>7</sup> Birjand University of Medicine, Birjand, Iran

<sup>1</sup> Sinus and Surgical Endoscopic Research Center, Faculty of Medicine, Mashhad University of Medical Sciences, Mashhad, Iran

systemic antifungal and aggressive serial surgical intervention appears to be effective in reducing mortality in most patients.

**Keywords** Invasive fungal rhinosinusitis · Immunocompromised · Diabetes mellitus · Leukemia

## Introduction

Fungal sinusitis can be categorized into non-invasive and invasive groups. While non-invasive fungal sinusitis does not exhibit the penetration of mucosa by hyphae, in invasive fungal sinusitis hyphae do invade the mucosa. Acute invasive fungal sinusitis (AIFRS) is considered the most aggressive form of fungal sinusitis. It can be more commonly found in patients who are immunocompromised and notably can lead to serious morbidity and mortality. Immunosuppression in these patients can be a result of widespread sources including hematologic malignancies, diabetes mellitus, solid organ or bone marrow transplantation, chemotherapy-induced neutropenia, and advanced AIDS. Clinical presentation is usually significant with sudden evolution of facial pain, fever, epistaxis, and nasal congestion. Involvement of the orbit can result in attenuation of vision, while extension into the sinus or intracranial compartments can lead to proptosis or neurological impairments, respectively [1, 2]. The development of the disease occurs over a number of days, but no longer than a few weeks, and can commonly lead to vascular invasion and systemic dissemination [2]. Infection is often thought to arise in the nasal cavity (commonly the middle turbinate) and progress to the paranasal sinuses [3]. This suggests involvement of multiple fungal agents, such as *Aspergillus* species (commonly in neutropenic patients), *Zygomycetes* (commonly in diabetic patients), *Rhizopus* species, *Absidia* species, *Mucor* species, and *Rhizomucor* species. Unlike the chronic variant, on non-contrast CT scans of acute invasive fungal sinusitis, sinonasal hyperdensities are not normally seen. CT scans have been most useful in pinpointing bony changes. Other findings include opacification of the sinus, mucosal thickening, bone deterioration, and accumulation of fat on the exterior of the sinus. Patients should be consistently surveyed for evidence of any other issues. Disease extension past the sinuses, particularly into the orbit and cranium, should be paid close scrutiny.

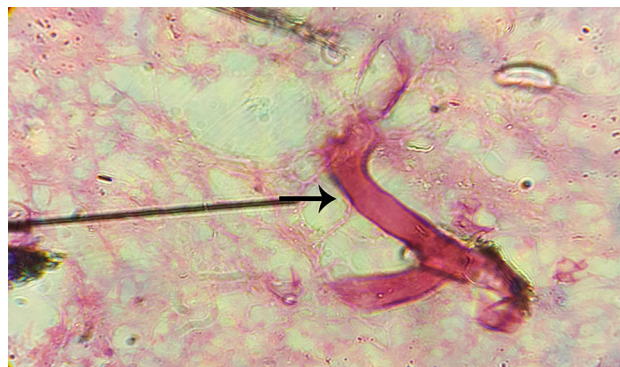
Most paramount to successful attenuation of infection is prompt and aggressive medical care, surgical intervention, and the treatment of underlying causes, such as neutropenia and elevated blood sugars. The administration of systemic antifungals (e.g., amphotericin B and posaconazole) and vital surgical debridement are commonly necessary.

Mortality remains high (18–80 %), even in spite of modern control mechanisms, and is particularly elevated in patients for whom corrective measures to combat neutropenia are unavailable [2–4]. It has been noted that the mortality of at-risk patients who receive direct and diligent surveillance can be as low as 18 % [4].

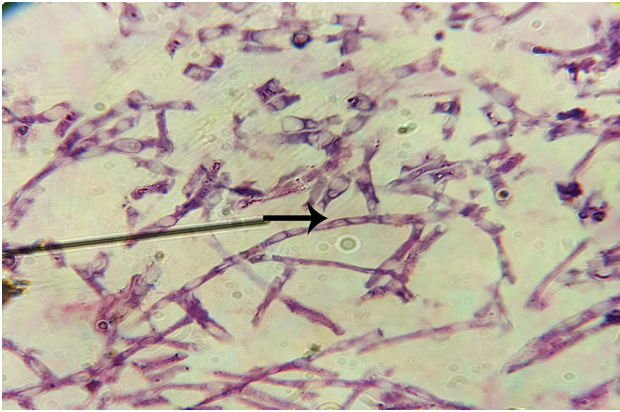
## Methods and materials

We prospectively analyzed the outcomes of 18 patients referred to the Department of Otorhinolaryngology from the Departments of Hematology and Infectious Disease of Mashhad University of Medical Sciences from January 2014 to March 2015. Age, sex, comorbidities, presenting signs and symptoms, imaging results, pathology findings, culture results, medical and surgical management approaches, and disease outcomes were documented. Computed tomography (CT) scans were obtained for all patients, while magnetic resonance imaging (MRI) scans were used when suspicions arose of orbital, cavernous sinus, or cranial extension.

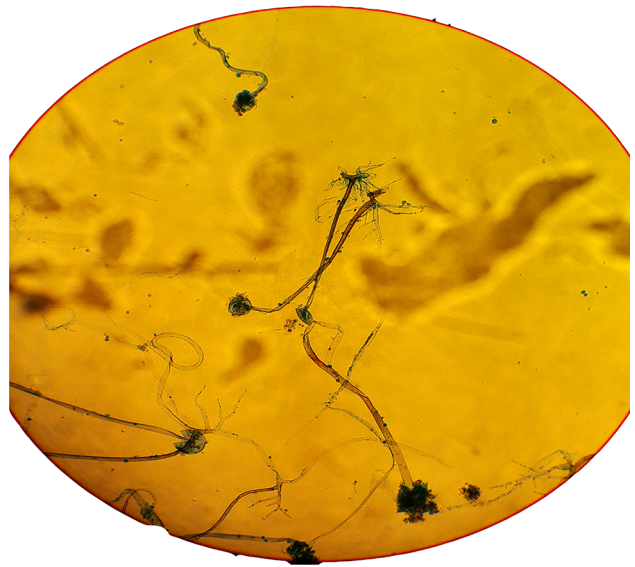
Biopsies were taken from all suspected patients for histopathologic evaluation and culture analysis. The histopathologic diagnosis was determined from the morphology using hematoxylin and eosin (H&E), periodic acid-Schiff, and Gomori's methenamine silver staining (Figs. 1, 2). The patients were considered to be positive when the histopathologic findings showed fungal elements invading the tissue and causing tissue necrosis. To obtain cultures, the samples were inoculated in Sabouraud dextrose agar (SDA) with chloramphenicol (50 µg/mL). SDA plates were incubated at 37 °C to enhance the growth of fungi. All media were incubated for 2 weeks and were examined daily. To study the morphologic characteristics and identify fungal organisms, slide cultures were prepared from each positive culture (Figs. 3, 4).



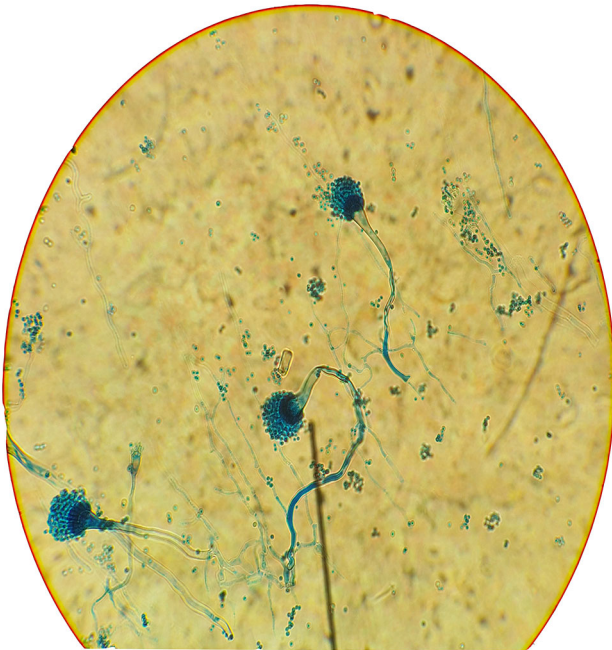**Fig. 1** Histopathological examination of a biopsy showing broad, not septate hyphae with nearly right-angle branching after hematoxylin eosin staining, characteristic of an agent of mucormycosis



**Fig. 2** Histopathological examination of a biopsy showing dichotomously branched septate hyphae after hematoxylin eosin staining, characteristic of an agent of aspergillosis



**Fig. 4** Microscopic appearance of *Rhizopus oryzae* in culturing



**Fig. 3** Microscopic appearance of *Aspergillus fumigatus* in culture

All patients were medically treated with amphotericin B. Also after histology confirmed fungal invasion, patients underwent serial endoscopic debridement until negative biopsy results were obtained. The surgical plan was determined by the extension of the infection so that we got healthy border. All cases underwent endoscopic debridement and those with skin or orbital involvement the combined approach (endoscopy and open approach) was used to eradicate infection. The extension of endoscopic surgery from creating a common cavity including wide antrostomy,

complete ethmoidectomy, sphenoidotomy type III and draft III to a partial resection of middle turbinate in limited disease was varied. Underlying disorders were managed by hematologists and infectious disease specialists.

## Results

The mean age was  $39.56 \pm 20.66$  years (range 2–75). Demographic data is listed in Table 1. The most common underlying disease was diabetes mellitus (50 %) and leukemia (44.44 %). Mucosal biopsy confirmed fungal invasion to the nasal mucosa, with *Rhizopus oryzae* (55.56 %), *Absidia mucor* (16.67 %) and *Aspergillus fumigatus* (27.78 %) as the main fungi. Headache and facial pain (77.8 %), facial paresthesia (55.6 %) and ophthalmoplegia (33.3 %) were the most common symptoms and signs (Table 2). CT scan and endoscopic findings showed various stages of sinonasal (100 %), pterygopalatine fossa (55.56 %), orbital (44.45 %) and cerebral (5.56 %) involvement. All patients underwent serial surgical debridement (frequency  $3.78 \pm 1.80$  times; range 2–8) simultaneously with systemic antifungal therapy and control of the disease. The most extensive case with brain involvement survived and recovered with no evidence of recurrent disease following treatment. All patients were considered cured after two endoscopic negative histopathologic evaluations. Three patients (16.67 %) died, one from uncontrolled leukemia and two due to renal failure not attributed to fungal infection. Patients' data are listed in Table 3.



**Table 1** Demographic data for 18 patients with invasive fungal sinusitis

Variable	Number	Frequency (%)
Total cases	18	100
Sex		
Male/female	7/11	38.9/61.1
Underlying diseases		
Diabetes	9	50
Diabetic ketoacidosis	7	38.9
New onset diabetes	2	11.1
Hematologic malignancy (AML/ALL)	8(4/4)	44.4(22.2/22.2)
Autoimmune disorders (SLE)	1	5.6
Chemotherapy (NHL)	1	5.6
Disease extension		
Orbit	8	44.4
Intracranial	1	5.6
Hard palate	10	55.6
Skin	3	16.7
Surgical therapy		
Endoscopic	15	83.3
Conventional	1	5.6
Combine	2	11.1
Orbital exenteration	2	11.1
Antifungal therapy		
Amphotericin B	15	83.3
Voriconazole/Posaconazole	2.7	11.1/38.9
Outcome		
Survived	15	83.3
Recovery without morbidity	12	66.7
Recovery with sequel	6	33.3
Mortality	3	16.7

## Discussion

AIFRS is the most aggressive form of fungal infection, with a high rate of morbidity and mortality, yet there is no standardized protocol for the management of this disorder. In this study, we have prospectively examined disease progression in and outcomes of patients with this infection who were referred to our department for head and neck surgery. We devised and used a particular plan to manage patients with AIFRS using a protocol developed with the help of specialists in the departments of hematology and infectious diseases at our university. Serial debridements were performed until negative culture results were achieved and histological examination was normal. Patients subsequently underwent periodic ambulatory endoscopic evaluation each month to ensure the eradication of disease.

**Table 2** Presenting sign and symptoms among AIFRS patients

Sign or Symptom	Number	Frequency (%)
Headache	11	61.11
Facial numbness	10	55.55
Ophthalmoplegia	6	33.33
Proptosis	5	27.78
Facial pain	4	22.22
Fever	4	22.22
Visual loss	4	22.22
Diplopia	3	16.67
Palatal necrosis/ulcer	3	16.67
Nasal discharge	2	11.11
Facial nerve palsy	2	11.11
Orbital cellulitis	2	11.11
Altered mental status	2	11.11
Nasal congestion	2	11.11

AIFRS presentation may be variable, so studying different case series and case reports can help provide insight into the symptomatology of this condition. The most common presenting symptoms of our patients were headache and facial pain (77.8 %), facial paresthesia (55.6 %), and ophthalmoplegia (33.3 %). In a case series with six patients by Abu El-Naaj, symptoms, such as pain mimicking sinusitis, facial swelling, oral or dental pain, and fever were seen in most patients [5]. Kursun et al. reported fever (79 %), periorbital cellulitis (75 %), and periorbital oedema (70 %) as the most frequently encountered signs and symptoms in their study [6]. The most common symptoms in the 14 cases reported by Ketenci et al. [7] were fever, facial edema, facial pain, and nasal obstruction. On initial examination, nine (64 %) patients had cutaneous and/or palatal necrosis (three had both palatal and skin necrosis). Of these, five (35 %) also had ophthalmoplegia and blindness. Four (29 %) patients also had facial palsy [7]. In a review article by Turner et al. that analyzed 52 studies comprising a total of 807 patients, the most common presenting symptoms in patients with AIFRS were swelling (64.5 %), fever (62.9 %), and nasal congestion (52.2 %) [8].

In our study, the most common underlying disorders were diabetes mellitus (50 %) and leukemia (44.44 %). We had one case of systemic lupus erythematosus (SLE) with an extended mucormycosis infection and altered mental status that finally died of renal failure. Another patient in our case series was undergoing chemotherapy for non-Hodgkin's lymphoma (NHL). In the Kursun et al. series, the most common underlying disease was diabetes mellitus, and to a lesser extent, hematological malignancies and chronic renal insufficiency [6]. In three other studies, the

**Table 3** Patients' data list

No	Age	Sex	Underlying disease	Fungal type	Medicine	Surgery	Surgical frequency	Sequel	Out come
1	27	Female	SLE	<i>Rhizopus o</i>	Am	Combined	5	Disfigurement	Survived
2	61	Female	Diabetes	<i>Rhizopus o</i>	Am	Endoscopic	4	No	Dead
3	20	Female	AML	<i>Aspergillus f</i>	Am/PO	Endoscopic	2	No	Survived
4	2	Female	ALL	<i>Aspergillus f</i>	Am	Endoscopic	3	No	Survived
5	28	Female	AML	<i>Rhizopus o</i>	Am/PO	Endoscopic	4	No	Survived
6	40	Female	Diabetes	<i>Rhizopus o</i>	PO	Endoscopic	4	Visual loss	Survived
7	13	Male	ALL	<i>Aspergillus f</i>	VO	Endoscopic	2	No	Survived
8	47	Male	AML	<i>Aspergillus f</i>	Am/PO	Endoscopic	3	No	Dead
9	60	Female	AML	<i>Absidia m</i>	Am	Conventional	2	Disfigurement	Dead
10	48	Female	Diabetes	<i>Absidia m</i>	Am	Endoscopic	6	Facial palsy Visual loss	Survived
11	70	Male	Diabetes	<i>Rhizopus o</i>	Am	Endoscopic	3	No	Survived
12	28	Female	ALL	<i>Aspergillus f</i>	Vo	Endoscopic	3	No	Survived
13	75	Male	Diabetes	<i>Rhizopus o</i>	Am	Endoscopic	2	No	Survived
14	20	Male	ALL	<i>Rhizopus o</i>	Am	Endoscopic	2	No	Survived
15	43	Female	Diabetes	<i>Absidia m</i>	Am	Combined	3	No	Survived
16	64	Male	Diabetes	<i>Rhizopus o</i>	Am	Endoscopic	8	No	Survived
17	30	Female	Diabetes	<i>Rhizopus o</i>	Am/PO	Endoscopic	5	Disfigurement Visual loss	Survived
18	35	Male	NHL	<i>Rhizopus o</i>	Am/PO	Endoscopic	7	Visual loss	Survived

Am Amphotericin B, PO Posaconazole, VO Voriconazole, *Aspergillus f* *Aspergillus fumigatus*, *Rhizopus o* *Rhizopus oryzae*, *Absidia m* *Absidia mucor*

most common predisposing factor and leading concomitant diseases was also diabetes mellitus [7, 9–13]. Turner et al. found the presence of diabetes, hematologic malignancies, corticosteroid use, renal or liver failure, organ transplantation, AIDS, and autoimmune disease in 47.8, 39.0, 27.6, 6.6, 6.3, 2.3, and 1.2 % of their patients, respectively [8].

All patients in our cohort were treated with a combination of antifungal medications and surgery. The majority received intravenous amphotericin B and underwent serial endoscopic resection with a mean frequency of  $3.78 \pm 1.80$  times. Posaconazole was used only in two patients with extensive *Aspergillus fumigatus* disease and elevated creatinine secondary to amphotericin B and voriconazole use. According to different studies, this is a routine approach when treating patients affected by this kind of fungal infection [5–10]. However, in one study cottonoid pledgets soaked in amphotericin B solution were placed in the nasal cavity after surgery [9]. In our study, most surgeries were performed endoscopically, and serial debridements and endoscopic follow-up evaluation were carried out each week. In a review article by Turner et al. [8], most patients were treated with a combination of surgery and antifungal treatment. In this review, endoscopic and open approaches were used 46.4 and 41.4 % of the time, respectively, while in our experience 83.34 % of cases underwent an endoscopic approach. We used combined endoscopic/open approaches

and only open approaches 11.11 and 5.55 % of the time, respectively. In the Turner et al. [8] review article, orbital exenteration was required in approximately 20 % of cases, which is comparable to our series (11.11 %), and liposomal formulations of amphotericin B were administered to nearly 15.0 % of patients. Unfortunately, this option was not available in our department.

Confirmation of the diagnosis of AIFRS requires the presence of fungal elements within the submucosal tissues of the infected nasal cavity and paranasal sinuses. Many fungal species cause invasive fungal infection including *Rhizopus*, *Mucor*, *Rhizomucor*, and *Aspergillus*. The most common invasive fungal organisms confirmed by culture in our case series were *Rhizopus oryzae* (55.56 %), *Aspergillus fumigatus* (27.78 %), and *Absidia mucor* (16.67 %). All other studies that we review here reported only the Mucorales species [5–7, 9, 10]. Even Turner et al. [8] did not mention the individual fungal species. Only in one publishing review article from Iran, *Rhizopus* species were the most common, followed by *Mucor* species (51.7, 17.2 %, respectively) [11].

Despite medical and surgical improvements in the management of this kind of infection, mortality and morbidity rates remain high. In our case series, the mortality rate among patients with a mean follow-up of  $9.11 \pm 2.51$  months was 16.67 %, of which two deaths were caused by renal failure.

One was an SLE patient with a fungal infection that extended to the forehead, cheek skin, and both orbits, and showed evidence of cerebritis (presenting with altered mental status). This patient's fungal infection was considered to be under control after 5 surgical debridements and antifungal therapy, but the patient finally died due to renal failure under dialysis. The other mortality was in a patient with AML and diabetes whose fungal infection was under control. This patient did not complete his treatment protocol for leukemia and died from his underlying disorder. The underlying disorder of the patients who died was leukemia (AML) and SLE. Each of these cases exhibited a certain species of fungus, namely *Rhizopus oryzae*, *Aspergillus fumigatus*, or *Absidia mucor*. The survival rate reported in the literature is variable and ranges from 20 to 80 % [3, 6–11, 14, 15]. In the six reported cases by Abu El-Naaj, the mortality rate was even higher than 80 %; five patients died due to their underlying illness and one died due to uncontrolled spreading of mucormycosis. Surprisingly, the only surviving case was the one with the most extensive form of the disease with brain invasion who clinically recovered with no evidence of recurrent disease following the surgical management [5]. The overall survival rate of the 807 cases that were reviewed by Turner et al. was 49.7 % while ours was 83.3 %. This significantly higher survival rate may be due to early diagnosis, aggressive surgical debridement [14, 16, 17], and amphotericin B [17, 18] use, which have been reported as improving prognosis. Hematologic malignancy [9, 14], advanced ages [17], and extension to the cranium [17, 19, 20] or orbit [21] are among negative prognostic factors that may cause fluctuations between outcomes of various reports. Our favorable results as compared with other studies may be due to close observation and early diagnosis of susceptible patients, who underwent diagnostic endoscopy whenever there were sinonasal symptoms and fever of unknown origin. Other factors included early management and aggressive serial debridement even for patients with low a platelet count (the mean platelet count of patients with hematological malignancies at the time of first debridement was 30,000), the presence of invasive aspergillus spores into the study, and irrigation of the sinonasal cavity with low concentrations of H<sub>2</sub>O<sub>2</sub> (1 %). The age of patients, underlying diseases, level of extension of the infection, and medical treatment approaches were comparable to the Turner review article [8].

It seems that early diagnosis with clinical suspicion of this kind of infection among diabetic and immunocompromised patients who possess facial pain, discomfort or paresthesia, facial swelling or cellulitis, fever, and new onset of progressive sinusitis over a period of hours or days should be kept in mind, and immediate management with antifungal therapy as well as rapid initiation of surgical debridement could affect the prognosis of the patients and improve the potential for survival.

## Conclusion

AIFRS can be successfully treated with a combination of serial endoscopic surgical debridements and antifungal medications. The endoscopic approach is suitable for patients diagnosed in the early stages of the disease and provides a less traumatic option for those patients who are already in poor condition. Open surgery should be preferred in the presence of intraorbital extension, palatal, and/or intracerebral involvement. Reversing the underlying disease process and immunosuppression is as important as the surgical and antifungal treatment.

## Compliance with ethical standards

**Conflict of interest** None.

## References

- Momeni AK, Roberts CC, Chew FS (2007) Imaging of chronic and exotic sinonasal disease: review. *AJR Am J Roentgenol* 189(6):S35–S45
- Aribandi M, McCoy VA, Bazan C (2007) Imaging features of invasive and noninvasive fungal sinusitis: a review. *Radiographics* 27(5):1283–1296
- Gillespie MB, O'Malley BW, Francis HW (1998) An approach to fulminant invasive fungal rhinosinusitis in the immunocompromised host. *Arch Otolaryngol Head Neck Surg* 124(5):520–526
- Parikh SL, Venkatraman G, DelGaudio JM (2004) Invasive fungal sinusitis: a 15-year review from a single institution. *Am J Rhinol* 18(2):75–81
- Abu El-Naaj I, Leiser Y, Wolff A, Peled M (2013) The surgical management of rhinocerebral mucormycosis. *J Craniomaxillofac Surg* 41(4):291–295
- Kursun E, Turunc T, Demiroglu YZ, Alışkan HE, Arslan AH (2015) Evaluation of 28 cases of mucormycosis. *Mycoses* 58(2):82–87
- Ketenci I, Unlü Y, Kaya H, Somdaş MA, Konaş O, Öztürk M, Vural A (2011) Rhinocerebral mucormycosis: experience in 14 patients. *J Laryngol Otol* 125(8):16
- Turner JH, Soudry E, Nayak JV, Hwang PH (2013) Survival outcomes in acute invasive fungal sinusitis: a systematic review and quantitative synthesis of published evidence. *Laryngoscope* 123(5):1112–1118
- Saedi B, Sadeghi M, Seilani P (2011) Endoscopic management of rhinocerebral mucormycosis with topical and intravenous amphotericin B. *J Laryngol Otol* 125(8):807–810
- Bellazreg F, Hattab Z, Meksi S, Mansouri S, Hachfi W, Kaabia N, Ben Said M, Letaief A (2014) Outcome of mucormycosis after treatment: report of five cases. *New Microbes New Infect* 6:49–52
- Vaezi A, Moazeni M, Rahimi MT, de Hoog S, Badali H (2016) Mucormycosis in Iran: a systematic review. *Mycoses*. doi:10.1111/myc.12474 (Epub ahead of print)
- Kermani W, Bouttay R, Belcadhi M, Zaghrouani H, Ben Ali M, Abdelkéli M (2016) ENT mucormycosis. Report of 4 cases. *Eur Ann Otorhinolaryngol Head Neck Dis* 133(2):83–86. doi:10.1016/j.anorl.2015.08.027 (Epub 2015 Sep 7)
- Mohammadi R, Meidani M, Mostafavizadeh K, Iraj B, Hamedani P, Sayedain SM, Mokhtari M (2015) Case series of rhinocerebral mucormycosis occurring in diabetic patients. *Caspian J Intern Med* 6(4):243–246 (Fall)

14. Chen CY, Sheng WH, Cheng A, Chen YC, Tsay W, Tang JL, Huang SY, Chang SC, Tien HF (2011) Invasive fungal sinusitis in patients with hematological malignancy: 15 years experience in a single university hospital in Taiwan. *BMC Infect Dis* 22(11):250
15. Mohindra S, Mohindra S, Gupta R, Bakshi J, Gupta SK (2007) Rhinocerebral mucormycosis: the disease spectrum in 27 patients. *Mycoses* 50(4):290–296
16. Khor BS, Lee MH, Leu HS, Liu JW (2003) Rhinocerebral mucormycosis in Taiwan. *J Microbiol Immunol Infect* 36(4):266–269
17. Sun HY, Forrest G, Gupta KL, Aguado JM, Lortholary O, Julia MB, Safdar N, Patel R, Kusne S, Singh N (2010) Rhino-orbital-cerebral zygomycosis in solid organ transplant recipients. *Transplantation* 90(1):85–92
18. Kara IO, Tasova Y, Uguz A, Sahin B (2009) Mucormycosis-associated fungal infections in patients with haematologic malignancies. *Int J Clin Pract* 63(1):134–139
19. Bhadada S, Bhansali A, Reddy KS, Bhat RV, Khandelwal N, Gupta AK (2005) Rhino-orbital-cerebral mucormycosis in type 1 diabetes mellitus. *Indian J Pediatr* 72(8):671–674
20. Dhiwakar M, Thakar A, Bahadur S (2003) Improving outcomes in rhinocerebral mucormycosis—early diagnostic pointers and prognostic factors. *J Laryngol Otol* 117(11):861–865
21. Bhansali A, Bhadada S, Sharma A, Suresh V, Gupta A, Singh P, Chakarbarti A, Dash RJ (2004) Presentation and outcome of rhino-orbital-cerebral mucormycosis in patients with diabetes. *Postgrad Med J* 80(949):670–674